



## Other Abdominal Conditions

## Natural orifice endoluminal technique (NOEL) for the management of congenital duodenal membranes

Jonathan Goring<sup>a</sup>, Sara Isoldi<sup>b</sup>, Shishu Sharma<sup>a</sup>, Filippo Torroni<sup>b</sup>, Sean Marven<sup>a</sup>, Paola De Angelis<sup>b</sup>, Mike Thomson<sup>a,\*</sup><sup>a</sup> Sheffield Children's Hospital, Sheffield, United Kingdom<sup>b</sup> Bambino Gesù Children's Hospital, Rome, Italy

## ARTICLE INFO

## Article history:

Received 7 October 2019

Accepted 26 October 2019

## Key words:

Duodenal stenosis

Duodenal web

Diaphragm dilatation

Endoscopic intervention

## ABSTRACT

**Purpose:** Congenital Partial Duodenal Obstruction (CPDO) caused by membranes/webs/diaphragms has traditionally been managed by open or laparoscopic duodenoduodenostomy or duodenojejunostomy. We report a two center case series where Natural Orifice Endoluminal technique (NOEL) was used to treat children with CPDO.

**Methods:** A retrospective case series was evaluated. Data collected included the duration of procedure, postoperative complications, length of stay, and need for further procedures.

**Results:** Fifteen patients were treated over a 10 year period by NOEL technique for late presenting CPDO. Four patients were managed at Sheffield Children's Hospital (Center A, UK), and 11 patients were managed in Bambino Gesù Hospital of Rome (Center B, Italy). 20% of the patients had more than one duodenal obstructing membrane. Both balloon dilatation and membrane incision techniques were used. Median follow up was 23 months (range 2–69) in Center A and 18 months (range 7–58) in Center B, 60% of patients were successfully treated with 1 NOEL procedure. 20% required 2 or 3 procedures to achieve long term luminal patency. 20% required surgery after NOEL failed to treat the partial obstruction definitively. One patient in Center A required radiological drainage of a retroperitoneal collection following perforation during NOEL.

**Conclusion:** NOEL technique is feasible and effective in selected children with CPDO. Both balloon dilatation and incision techniques can be used. Care must be taken to rule out a second distal obstruction. We would recommend that all infants and children with CPDO owing to a fenestrated membrane should be considered for NOEL.

**Type of study:** Case series.

**Level of evidence:** Level IV.

© 2019 Published by Elsevier Inc.

Congenital Partial Duodenal Obstruction (CPDO) secondary to what is variably referred to in the literature as a web, diaphragm, membrane, windsock or stenosis is a rare cause of intestinal obstruction with an estimated incidence of 1:10,000–40,000 live births [1]. While complete obstruction of the duodenum is frequently detected antenatally, partial obstruction may present later and the diagnosis can often be delayed. Traditional management has been surgical bypass or resection of the obstructing mucosal membrane either through a laparotomy or laparoscopically [2,3]. Endoscopic treatment of CPDO has been reported to achieve luminal patency without recourse to trans peritoneal surgical interventions. We report our experience of treating CPDO using Natural Orifice Endo-Luminal technique (NOEL) across two tertiary pediatric centers.

## 1. Methods

Retrospective review of patients with CPDO managed at Sheffield Children's Hospital (Center A, UK), and Bambino Gesù Hospital of Rome (Center B, Italy), between September 2007 and December 2018 treated using NOEL technique. NOEL technique was defined as any endoscopic method that treated the CPDO without recourse to open or laparoscopic surgery. Data collected included patient demographics, mode of presentation, procedure performed, complications and need for redo procedures. Procedures involving endoscopic incision and balloon dilatation of other luminal gastrointestinal obstructions were well established in both centers. Parents were counseled on both NOEL techniques and transperitoneal approaches and fully informed consent was gained. Institutional approvals for the retrospective patient note reviews were acquired. Patients from Center B already published in earlier case reports were excluded.

\* Corresponding author at: Sheffield Children's Hospital, Clarkson Street, Sheffield, S10 2TH, UK. Tel.: + 44 01142717000

E-mail address: [mike.thomson1@nhs.net](mailto:mike.thomson1@nhs.net) (M. Thomson).

**Table 1**  
Patient demographics and mode of presentation.

Patient Number	Age at Presentation (years)	Presenting Features	Comorbidities
Center A			
1	1.8	vomiting	n/a
2	5.3	vomiting	Trisomy 21
3	12.1	vomiting	VSD, previous duodenal atresia
4	4.1	vomiting	previous esophageal atresia
Center B			
5	1	vomiting, dehydration	n/a
6	0.25	vomiting	previous duodenal atresia
7	24	epigastric pain	Trisomy 21, tetralogy of Fallot
8	2	vomiting	von Willebrand factor deficiency
9	1.4	vomiting	Trisomy 21, complete atrioventricular canal defect, incomplete annular pancreas
10	0.8	vomiting	incomplete annular pancreas
11	0.1	vomiting	n/a
12	0.3	vomiting	n/a
13	n/a	recurrent pancreatitis	n/a
14	0.7	vomiting	n/a
15	17	abdominal pain,	Trisomy 21, complete atrioventricular canal defect

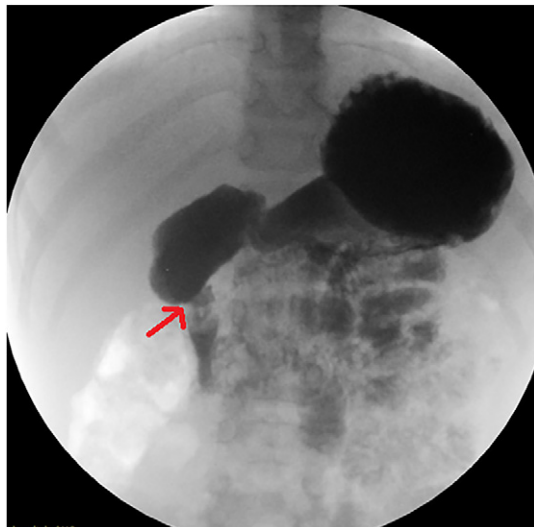
**2. Results**

We identified 15 children across the two centers (4 in Center A and 11 in Center B) treated using NOEL for CPDO between September 2007 and December 2018. Patient demographics, presenting features and comorbidities are presented in Table 1.

All children underwent an upper gastrointestinal (UGI) contrast study to make the diagnosis of CPDO before proceeding to endoscopy (Fig. 1). In addition, 3 patients underwent cross sectional imaging (2 CTs and 1 MRI). The MRI in Patient 2 was helpful for preoperative planning as it demonstrated the ampulla of Vater opening into the membrane itself (Fig. 2).

A combination of endoscopic balloon dilatation and endoscopic sphincterotome (Cook Minitome, Bloomington, IN, USA) / electrocautery endoknife (Microknife, Boston Scientific Microinvasive, Natick, MA, USA) was used (Fig. 3). Center A employed a dual channel Olympus © endoscope to facilitate the use of the endoballoons to not only dilate the membrane but also to stabilize the membrane to allow more precise incisions (Fig. 4). Center B also employed endo ultrasound in 3 patients to facilitate location of the ampulla of Vater in relation to the membrane to minimize the risk of iatrogenic trauma to the biliary tree.

Operative details are shown in Table 2.



**Fig. 1.** UGI contrast study demonstrating partial obstruction in the second part of the duodenum and a dilated proximal duodenum consistent with a duodenal membrane (Red arrow).

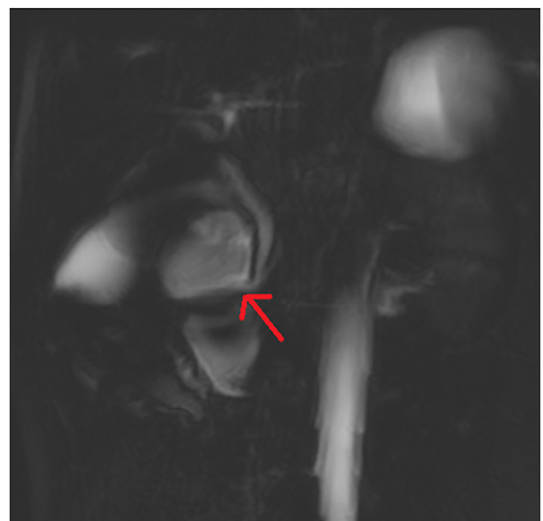
Median length of procedure was similar in both centers: 25 min (range 24–34 min) in Center A and 27 min (range 22–39 min) in Center B. All children from Center A were discharged after their first dilatation after 1 night in hospital. Median length of stay in Center B was 4 days (range 2–20). Combining both centers' data, NOEL achieved luminal patency after 1 procedure in 9/15 (60%) of cases. A further 3 patients (20%) required 1 (13%) or two (7%) repeated NOEL procedures to achieve luminal patency. Median follow up was 23 (range 2–69) months in Center A and 18 (range 7–58) months in Center B. The remaining 3 children underwent a surgical procedure following NOEL after subsequent diagnosis of annular pancreas ( $n = 2$ ) and persistent obstructive symptoms owing to a second distal duodenal web ( $n = 1$ ).

**2.1. Complications**

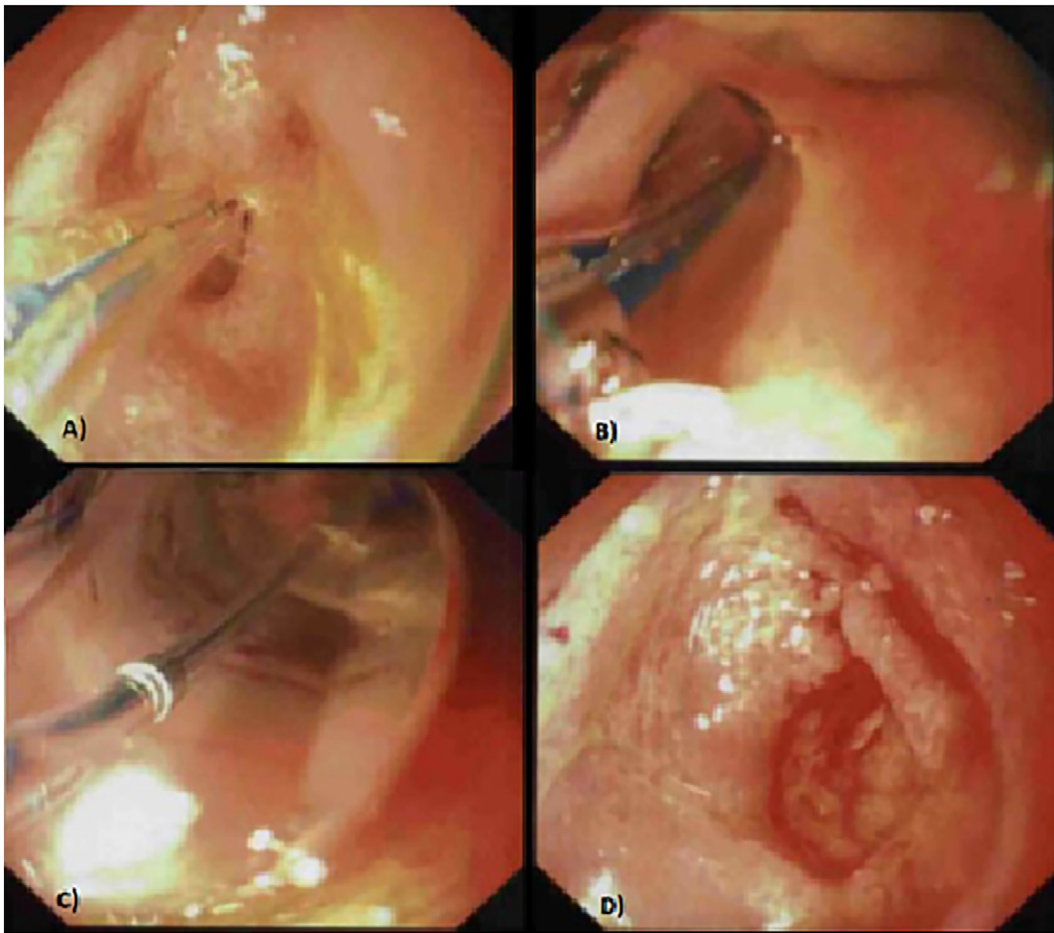
One patient developed melena after their first NOEL procedure that settled spontaneously. A second patient, on their third NOEL procedure developed a perforation in their duodenum leading to sepsis from a retroperitoneal collection diagnosed on CT. This was drained radiologically and the patient otherwise recovered uneventfully and was discharged.

**3. Discussion**

Congenital partial duodenal obstruction secondary to a fenestrated

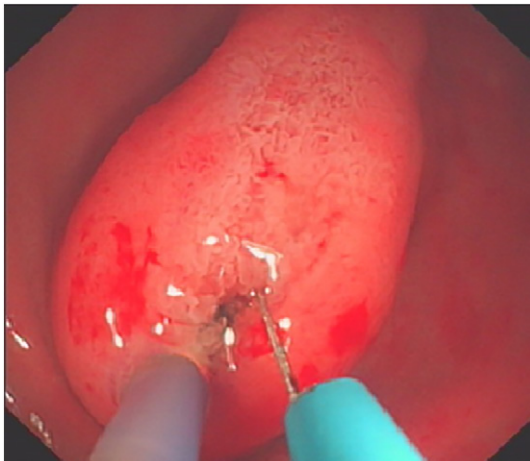


**Fig. 2.** MRCP of patient 2. The ampulla of Vater is seen entering at the level of web/membranous obstruction (Red arrow).



**Fig. 3.** Endoscopic images demonstrating the application of a balloon dilator through the perforation in the membrane/web (A and B), followed by balloon dilatation (C). (D) Luminal patency has been achieved.

web/diaphragm/membrane is an uncommon cause of partial intestinal obstruction. The aperture within the diaphragm can be of varying sizes, causing varying degrees of obstruction and as such the pathology may not be detected antenatally and present later in childhood or even adulthood [4,5] with symptoms that can mimic other conditions such as gastroesophageal reflux disease. The obstruction is most commonly found in the second part of the duodenum [1]. Historically these patients have been treated surgically either via a laparotomy or



**Fig. 4.** The dual channel endoscope facilitates the use of the balloon to stabilize the membrane to allow precise incision.

laparoscopically and outcomes have been good, however these techniques do pose potential immediate and longer term risks as well as being cosmetically suboptimal [2,3,6]. Specifically the risk of adhesive small bowel obstruction variably estimated at 6%–14% following laparotomies in infants and children would be eliminated if the peritoneum is not breached [7]. The use of endoscopic techniques to treat the intraluminal obstruction was first described in adults by Turnbull in 1980 using endoscopic biopsy forceps to disrupt the membrane [4] and the first case of CPDO treated in a child using a NOEL technique was by Okamatsu in 1989 [8]. Several techniques have subsequently been reported, including using the sphincterotome [9,10], laser ablation [5,11] and even through a preexisting gastrostomy using standard laparoscopic impedance controlled bipolar diathermy (Ligasure ©) [12].

Recently several small series have demonstrated good success rates with endoluminal balloon dilatation alone [13–15]. The largest single center series published to date reported successful medium term results using endoscopic balloon dilatation in 6 children as a first line treatment but recommended the use of electrocautery for residual obstruction following this [16]. To our knowledge our report represents the largest case series of endoscopic management of CPDO in children to date.

Complications of endoscopic therapy have been reported in the past [17] and in our series one patient developed a perforation during the procedure. This was treated without recourse to open surgery and occurred after the use of an endoscopic electrocautery knife. We also noted that several patients required more than one dilatation to achieve long term luminal patency and this should be discussed with parents when considering NOEL as a treatment option for CPDO.

**Table 2**  
Operative details for patients in series.

Patient number	Maximum balloon diameter	Use of endocutting	Early complications 1st dilatation	Length of stay (days)	Total endoscopic procedures	Comments
Center A						
1	10	yes (Endoknife)	no	1	3	Duodenal perforation after 3rd procedure
2	15	no	no	1	2	
3	20	no	no	1	1	
4	18	no	no	1	1	
Center B						
5	n/a	yes (Endoknife)	no	4	1	
6	n/a	yes (sphincterotome)	no	20	1	
7	n/a	yes (Endoknife)	no	2	1	
8	n/a	yes (Endoknife)	melena	7	1	
9	n/a	yes (sphincterotome)	no	7	1	subsequent surgery for annular pancreas
10	n/a	yes (sphincterotome)	no	7	1	subsequent surgery for annular pancreas
11	n/a	yes (Endoknife)	no	6	1	
12	n/a	yes (Endoknife)	no	3	1	subsequent surgery for second web
13	n/a	yes (Endoknife)	no	2	1	
14	n/a	yes (Endoknife)	no	4	2	Second web dilated
15	n/a	yes (Endoknife)	no	2	1	

Several authors have highlighted the high rate of associated cardiovascular, chromosomal and gastro intestinal anomalies associated with CPDO [3,18]. Our study also found these associations to be common in this patient population and this highlights the need to rule out these conditions in children with CPDO.

The presence of a duodenal obstruction either complete or partial should always prompt the endoscopist to search for a second, more distal obstruction. This uncommon anomaly has been described previously [19] and in our series we encountered 3 patients (20%) with this anatomical variant. Any patient not responding as expected after initial web incision/dilatation should prompt an active search for a second point of obstruction not identified on initial evaluation as well as recurrence at the primary site.

Cases where endoscopic therapy was only partially successful were strongly associated with an annular pancreas. While uncommon, it is our experience that this defect reduces the chances of endoscopic therapy succeeding in the long term and highlights the importance of patient selection when considering NOEL technique for CPDO. As such we would advocate performing MRI in children preoperatively to assess the pancreatic anatomy and to consider a primary surgical approach if annular pancreas is found. MRI may also highlight the relative position of the ampulla of Vater to the membrane. If found to be within the membrane the use of cutting techniques may be inadvisable.

In conclusion, the NOEL technique for treating CPDO is both feasible and effective in the majority of children and offers the possibility of scarless minimally invasive resolution of symptoms. Our experience has shown that both incision techniques and dilatation of the membrane are effective in experienced hands; however, the practitioner must be aware of the possibility of a second web at a more distal location and actively exclude this. We would recommend that all infants and children with CPDO owing to a fenestrated membrane should be considered for NOEL and this should form part of the discussion with parents when considering treatment modalities in this complicated group of children.

## References

- [1] Beeks AA, Gosche J, Giles H, et al. Case report endoscopic dilation and partial resection of a duodenal web in an infant. *J Pediatr Gastroenterol Nutr* 2009;48:378–81.
- [2] Chung PHY, Wong CWY, Ip DKM, et al. Is laparoscopic surgery better than open surgery for the repair of congenital duodenal obstruction? A review of the current evidences. *J Pediatr Surg* 2017;52:498–503.
- [3] Bailey PV, Tracy TF, Connors RH, et al. Congenital duodenal obstruction: a 32-year review. *J Pediatr Surg* 1993;28:92–5.
- [4] Turnbull A, Kussin S, Bains M. Radiographic and endoscopic features of a congenital duodenal diaphragm in an adult: a case report and review of the literature. *Gastrointest Endosc* 1980;26:46–8.
- [5] Gertsch P, Mosimann R. Endoscopic laser treatment of a congenital duodenal diaphragm in an adult. *Gastrointest Endosc* 1984;30:253–4.
- [6] Muensterer OJ, Hansen EN. Resection of a duodenal web using single-incision pediatric endosurgery. *J Pediatr Surg* 2011;46:989–93.
- [7] Lakshminarayan B, Hughes-Thomas AO, Grant HW. Epidemiology of adhesion in infants and children following open surgery. *Semin Pediatr Surg* 2014;23(6):344–8.
- [8] Okamatsu T, Arai K, Yatsuzuka M, et al. Endoscopic membranectomy for congenital duodenal stenosis in an infant. *J Pediatr Surg* 1989;24:367–8.
- [9] Torroni F, De Angelis P, Caldaro T, et al. Endoscopic membranectomy of duodenal diaphragm: pediatric experience. *Gastrointest Endosc* 2006;63:530–1.
- [10] DiMaio CJ, Kamal N, Hogan CM, et al. Pediatric therapeutic endoscopy: endoscopic management of a congenital duodenal web. *Gastrointest Endosc* 2014;80:166–7.
- [11] Kay GA, Lobe TE, Custer MD, et al. Endoscopic laser ablation of obstructing congenital duodenal web in the newborn: a case report of limited success with criteria for patient selection. *J Pediatr Surg* 1992;27(3):279–81.
- [12] Mora MC, Banever GT, Tirabassi MV, et al. Duodenal web resection via hybrid natural orifice transluminal endoscopic surgery (NOTES). *J Pediatr Surg Case Reports* 2015;3:87–9.
- [13] Poddar U, Jain V, Yachha S, et al. Congenital duodenal web: successful management with endoscopic dilatation. *Endosc Int Open* 2016;04:E238–41.
- [14] Asabe K, Oka Y, Hoshino S, et al. Modification of the endoscopic management of congenital duodenal stenosis. *Turk J Pediatr* 2008;50:182–5.
- [15] van Rijn RR, van Lienden KP, Fortuna TL, et al. Membranous duodenal stenosis: Initial experience with balloon dilatation in four children. *Eur J Radiol* 2006;59:29–32.
- [16] Huang MH, Bian HQ, Liang C, et al. Gastroscopic treatment of membranous duodenal stenosis in infants and children: report of 6 cases. *J Pediatr Surg* 2015;50:413–6.
- [17] Barabino A, Arrigo S, Gandullia P, et al. Duodenal web: complications and failure of endoscopic treatment. *Gastrointest Endosc* 2012;75:1123–4.
- [18] Paterson-Brown S, Stalewski H, Brereton RJ. Neonatal small bowel atresia, stenosis and segmental dilatation. *Br J Surg* 1991;78:83–6.
- [19] Barabino A, Gandullia P, Arrigo S, et al. Successful endoscopic treatment of a double duodenal web in an infant. *Gastrointest Endosc* 2011;73:401–3.